



## Treatment Updates

# Surgical Management of Allergic Rhinitis

## **SURGICAL MANAGEMENT OF ALLERGIC RHINITIS**

Surgical management of allergic rhinitis has traditionally been reserved for those cases refractory to medical management. The increasing cost of medically managing perennial allergic rhinitis means that the surgical management of this condition is gaining increasing prominence. Allergic rhinitis is the most common chronic condition of adolescence and is one of the most frequent diseases in the general population. About 20% of the population suffers from hayfever, another 5% has perennial rhinitis. Of the non-allergic rhinitis 20% of the general population suffers either continuously or intermittently from rhinitis. The cost of managing allergic rhinitis is of enormous expense to the community and is in fact third behind medications for cancer and medications for reflux and peptic ulceration. A large number of economic analyses of allergic rhinitis have been published and the cost of managing allergic rhinitis annually in the United States varies between 2 and 5 billion US dollars (2003 values). Extrapolating this data to the Australian population puts the cost of managing this condition locally at between 200 and 500 million AUS dollars annually.

While medical management of allergic rhinitis is effective at controlling symptoms in between 80 and 85% of individuals, use of current medication has certain potential problems. These include:

- Compliance with long-term use;
- Cumulative cost;
- Potential systemic side effects;
- Potential effects on the lining of the nose.

Hitherto, the surgical option has not been considered as primary treatment for allergic rhinitis because it often involves:

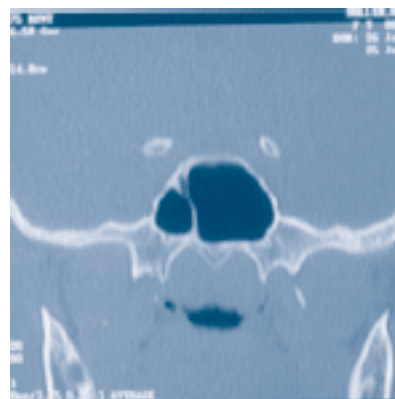
- General anaesthetic;
- Hospitalization;
- Significant cost;
- The beneficial effects of the surgical techniques were not consistently demonstrable for longer than 12 months.

With the evolution of newer surgical techniques, some of which can be done under local anaesthesia in an office setting, the surgical management of allergic rhinitis needs to be reexamined.

## **CONDITIONS APPROPRIATELY TREATED PRIMARILY BY SURGERY**

### **1. Adenoid Hypertrophy causing Significant Postnasal Obstruction.**

Adenoids undergo physiological hypertrophy at about the age of 2, become smaller and then become bigger at about the age of 5 and then slowly involute. If the adenoids, as illustrated in the above diagram, cause significant obstruction of the postnasal space and/or extend into the back of the nose, medical management, aimed at ameliorating the symptoms of allergic rhinitis will be ineffective and appropriate treatment is surgical, specifically Adenoidectomy, usually supplemented by Nasendoscopy and Powered Resection for any adenoid tissue extending through the posterior naso-choanae into the nose.

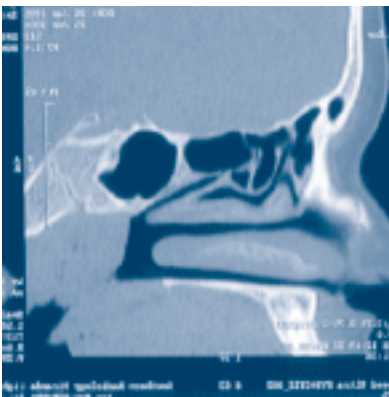


### **2. Massive Hypertrophy of Inferior Turbinates after Topical Vasoconstriction.**

In cases presenting with nasal obstruction due to turbinate hypertrophy an important diagnostic test is the local application of a sympathomimetic

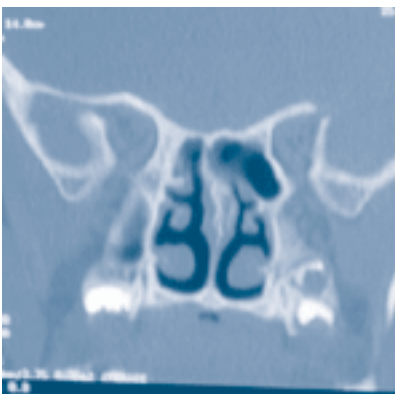


amine spray, such as Drixine or Atrovent. These sprays take about 8 minutes to achieve maximal vasoconstriction. If after 8 minutes of the spray in the nose the nose is re-examined and the inferior turbinate is still significantly swollen and hypertrophic, that tissue has lost a lot of its elastic recall, long-term management either with topical low-dose water-based steroid sprays and/or topical or oral antihistamines is unlikely to be ineffective. The appropriate treatment for this condition (as illustrated by the accompanying CT print) is surgical and involves Powered Inferior Turbinoplasty and Outfracture of the Inferior turbinates.



### 3. Polypoidal Degeneration of the Posterior

This is sometimes found to be the major cause of nasal obstruction. This condition does not respond to local or systemic medical management and is appropriately treated surgically, specifically by Endoscopic Removal using Powered Instrumentation.



## THE ROLE OF SURGERY IN CONJUNCTION WITH THE MEDICAL MANAGEMENT OF ALLERGIC RHINITIS.

There is no doubt that surgical management of allergic rhinitis has a significant contribution to make in the 15 to 20% of individuals whose symptoms cannot be controlled by maximal medical management.

A summary of the available surgical procedures is as follows:

### Outfracture of the Inferior Turbinates

This is perhaps the oldest surgical technique. It is a relatively simple procedure that is rarely done in isolation, but is usually combined with other nasal procedures. If used alone it affords symptom amelioration measured in months rather than years and is not a recommended current definitive treatment.

### Mucosal or Sub-Mucosal Diathermy of the Inferior Turbinates

Sub-mucosal diathermy is the preferred route insomuch as it causes no mucociliary scarring and does not interfere with mucociliary transfer. The erectile tissue between the bone of the inferior turbinate and the lining is obliterated by electrocautery with scarring. This technique involves an electrical burn; the burn is not controlled and often some damage to the mucosa occurs. It is associated with significant perioperative swelling and it is not common (?) to get scabbing or eschar of the inferior turbinate separating approximately one week postoperatively. Amelioration of symptoms is measured in months to years. The major disadvantages of this technique are:

- Post-operative crusting and scarring of the nose;
- Procedure performed under general anaesthesia;
- Procedure performed in a hospital setting;
- Most long-term studies indicate significant therapeutic effect for 2 years with diminution in benefit thereafter.

### Radiofrequency Ablation

Radiofrequency ablation can be either unipolar or bipolar. This is a newer technique using electrical energy at different frequency/intensity. The bipolar technique has the advantage of not spilling current into adjacent tissues. Controlled radiofrequency obliteration of erectile tissue occurs with minimal thermal damage to the underlying bone and periosteum or the overlying mucosa. Follow up results indicate symptom



amelioration in years. The advantage of this technique is that it can be performed under local anaesthesia in an office setting. The disadvantage is that the technology itself is relatively expensive and the disposable probe costs up to \$500.00 per procedure.

#### **Laser Reduction of Inferior Turbinates**

This can be performed using either carbon dioxide or argon lasers. Laser reduction is a transmucosal technique with attendant risk of damage to the mucosa and subsequent disruption of mucociliary transport. Follow up studies of laser turbinate reduction shows good symptom amelioration for up to 2 years with reduction in benefit thereafter. The major disadvantage of this technique is the expense of the laser technology. The procedure is usually performed under anaesthesia in a hospital setting, but can be performed under local anaesthesia in an office setting.

#### **Inferior Turbinoplasty using Powered Instrumentation**

This is one of the newer techniques for controlling hypertrophy of the inferior turbinates associated with allergic rhinitis. It is a sub-mucosal technique whereby the erectile tissue, periosteum and bone can be removed with minimal mucosal damage. This technique is often combined with outfracture of the inferior turbinates. It is usually performed under general anaesthesia in a hospital setting. Follow up studies show that symptoms are ameliorated for years. Some of the longest running studies have shown excellent symptom amelioration at 3 and 4 years post-operatively. Another advantage of this technique is that there is minimal crusting or eschar in the nose and the benefits of the operation tend to "kick in" on the 3rd or 4th post-operative day. The disadvantage of the technique is that it is performed under general anaesthesia in a hospital setting. The disposable blade used to perform the procedure is relatively inexpensive.

#### **Turbinectomy**

Excision of part, or the entire inferior turbinate is one of the older techniques for treating allergic rhinitis. It involves the surgical excision of mucosa, sub-mucosa, erectile tissue and bone. There are two basic techniques; removing the front end of the inferior turbinates or significantly trimming the turbinate along its entire length. Symptom amelioration is excellent and studies have shown significant benefits being recorded for more than 5 years post-operatively.

The disadvantage is that the technique is performed under general anaesthesia in a hospital setting and it is associated with a higher risk of

secondary haemorrhage than other surgical techniques. Because it gives the greatest increase in nasal cross-sectional area, theoretically problems with a hyperpatent nose, potentially leading to atrophic rhinitis in colder climates has to be considered.

#### **CONCLUSIONS**

The majority of people with allergic rhinitis are appropriately treated medically in the first instance, with the exception of those with:

- Adenoid hypertrophy
- Massive turbinate hypertrophy refractory to topical sympathomimetic amines
- Polypoidal degeneration of the posterior end of the inferior turbinate
- Large bilateral concha bullosae

Newer surgical techniques, specifically bi-polar radiofrequency ablation (which can be done under local anaesthesia in the rooms) and inferior turbinoplasty using powered instrumentation, have been shown to be effective and reliable in managing symptoms of allergic rhinitis for periods of greater than 3 years.

With the evolution of these new surgical techniques significant benefit in effectiveness can be shown in terms of

- Overall cost of procedure versus cost of medication
- Compliance
- Potential local side effects
- Potential systemic side effects, particularly if intercurrent inhalers are used for the management of asthma.

**If further information is required,  
please email us:  
[enquiries@earnosethroat.com.au](mailto:enquiries@earnosethroat.com.au)**